

Stroke

American Stroke
AssociationSM

JOURNAL OF THE AMERICAN HEART ASSOCIATION

A Division of American
Heart Association



Autoantibodies Against Oxidatively Modified Lipoproteins and Progression of Carotid Restenosis After Carotid Endarterectomy

Maria Vittoria Meraviglia, Elena Maggi, Giorgio Bellomo, Marco Corsi, Giovanna Fanelli and Fabio Minicucci

Stroke 2002;33:1139-1141

DOI: 10.1161/01.STR.0000014420.15948.2E

Stroke is published by the American Heart Association, 7272 Greenville Avenue, Dallas, TX 72514
Copyright © 2002 American Heart Association. All rights reserved. Print ISSN: 0039-2499. Online
ISSN: 1524-4628

The online version of this article, along with updated information and services, is located on the World Wide Web at:

<http://stroke.ahajournals.org/cgi/content/full/33/4/1139>

Subscriptions: Information about subscribing to Stroke is online at
<http://stroke.ahajournals.org/subscriptions/>

Permissions: Permissions & Rights Desk, Lippincott Williams & Wilkins, a division of Wolters Kluwer Health, 351 West Camden Street, Baltimore, MD 21202-2436. Phone: 410-528-4050. Fax: 410-528-8550. E-mail:
journalpermissions@lww.com

Reprints: Information about reprints can be found online at
<http://www.lww.com/reprints>

Autoantibodies Against Oxidatively Modified Lipoproteins and Progression of Carotid Restenosis After Carotid Endarterectomy

Maria Vittoria Meraviglia, MD; Elena Maggi, MD; Giorgio Bellomo, MD; Marco Corsi, BME; Giovanna Fanelli, MD; Fabio Minicucci, MD

Background—The purpose of this study was to determine whether LDL oxidation could play an important pathogenic role in early restenosis after carotid endarterectomy. An immunologic and biochemical study was performed on a group of patients who underwent carotid endarterectomy, and the degree of intima-media thickness was measured 6 months after surgery.

Summary of Report—Fifty-two consecutive patients were included in the study. The presence of antibodies against oxidized LDL in the serum at the time of surgery was evaluated and compared with echo Doppler flow imaging 6 months after the operation. A statistically significant correlation was found between the arterial wall thickness at the site of surgery and the absolute value of IgG antibodies against oxidized LDL ($P < 0.012$) and IgM immunocomplexes ($P < 0.043$).

Conclusions—The presence of antibodies against oxidized LDL at the time of surgery seems to predict a greater intima-media wall hyperplasia at 6 months after surgery, usually recognized as early restenosis. (*Stroke*. 2002;33:1139-1141.)

Key Words: carotid endarterectomy ■ carotid stenosis ■ lipoproteins, LDL ■ oxidative stress

The study of the natural history of carotid stenosis emphasizes the importance of oxidized LDL in the progression of the disease.¹ We investigated whether the same pathogenic mechanism may play a role in restenosis after endarterectomy or whether a different cause-effect relationship exists.

Subjects and Methods

We investigated 52 patients (37 men and 15 women, aged 67.3 ± 8.18 years) who underwent carotid surgery for symptomatic stenosis of $>75\%$.

The diagnosis of carotid atherosclerosis had been made by echo color-Doppler flow imaging, and the preoperative evaluation of each patient was made by intra-arterial digital subtraction angiography or MR angiography. After the patient had fasted for 12 hours, blood samples were collected from the forearm with the patient seated and with minimal vein compression. Blood was collected in EDTA test tubes (1 mg/mL) and centrifuged, within 1 hour, at 1500g for 30 minutes at 4°C.

To isolate LDL from plasma, we used the method described by Esterbauer et al.² LDL in vitro oxidation was then monitored by a spectrophotometer at 234 nm to detect conjugated diene formation, with the use of a Beckman DU-68 device. We then measured the lag phase, the peak time, and the propagation rate (Figure 1) following the same method described by Esterbauer et al.²

The antibodies against both native LDLs and oxidized LDLs were measured in patients' serum as well as the antibodies against

malondialdehyde (MDA)-LDL and MDA-human serum albumin (HSA) and immunocomplexes IgG and IgM.³

Six months after surgery, each patient underwent carotid echo Doppler sonography to study arterial wall aspects. All the examinations were performed by the same operator blinded with respect to antibody detection and clinical examination.

Sonographies were performed with an Acuson 128×P/10W device with an L538 5-MHz probe. Intima-media arterial wall thickness (IMT) was measured by echography, and the mean intima-media thickness (MIMT) in 3 different sites was calculated: pre-bifurcation (>5 mm before bifurcation, on the common carotid artery), peri-bifurcation (<5 mm before and <5 mm beyond bifurcation), and post-bifurcation (>5 mm beyond bifurcation). IMT was determined as the maximal distance, in each of the 3 sites, between the vessel surface near the lumen and the hyperechogenic zone inside the wall itself.

The edge of the operated zone appears as a vessel indentation, gradually sloping toward the internal carotid artery. At the site of the indentation a poorly echogenic layer is evident, which seems to form a double profile because of the adventitia and remaining media (usually no thicker than 1.5 to 2 mm), which remains the same over time.⁴

All data were processed by linear regression analysis with the use of BMDP statistical software.

Results

At 6 months after surgery, 15 subjects had an IMT >2.5 mm (11 patients before bifurcation, 2 patients beyond bifurcation,

Received September 27, 2001; final revision received December 10, 2001; accepted December 27, 2001.

From Servizio di Neurofisiologia, Ospedale San Raffaele, Milan (M.V.M., M.C., G.F., F.M.); Servizio di Pronto Soccorso e Accettazione, Ospedale Policlinico San Matteo, Pavia (E.M.); and Ospedale Maggiore, Novara (G.B.), Italy.

Reprint request to Fabio Minicucci, MD, Servizio di Neurofisiologia, Ospedale San Raffaele, Via Olgettina, 60, 20132 Milano, Italy. E-mail minicucci.fabio@hsr.it

© 2002 American Heart Association, Inc.

Stroke is available at <http://www.strokeaha.org>

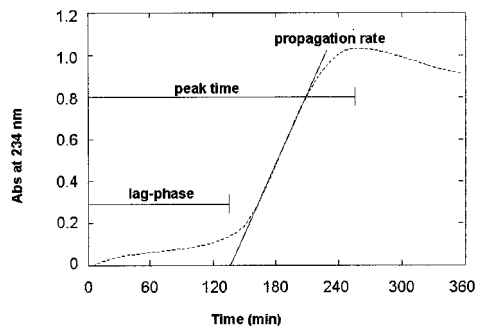


Figure 1. Kinetics of LDL in vitro oxidation. Increase of absorbance (Abs) of antibodies at 234 nm is due to transformation of polyunsaturated fatty acids with isolated double bindings into hydroperoxides with conjugated double bindings. Monitoring this parameter allows division of the LDL oxidation process into 3 time phases: (1) initial lag phase; (2) rapid increase of absorbance (propagation rate); and (3) decomposition or terminal phase (peak time).

and 2 patients along the internal carotid artery). The MIMT value in 5 of 52 patients was >2.5 mm. No correlation was shown with percent stenosis before surgery, type of plaque before surgery, or surgeon performing the operation. No correlation was found with clinical parameters such as high arterial blood pressure (69% of subjects), dyslipidemia (26%), diabetes (21%), obesity (7%), and smoking (22%).

A statistically significant correlation was evident between lag-phase duration and peri-bifurcation IMT ($P<0.0019$). A positive trend was also noted between lag-phase duration and pre-bifurcation ($P<0.096$) and post-bifurcation IMT ($P<0.054$). This determined a highly significant correlation ($P<0.008$) between MIMT of the whole carotid tract at the site of surgery and decrease of the lag phase.

No statistically significant correlation was shown between MIMT and antibodies against native LDL, while a significant correlation was revealed between MIMT and the absolute value of IgG antibodies against oxidized LDL ($P<0.012$) (Figure 2), for both the peri-bifurcation IMT ($P<0.032$) and post-bifurcation IMT ($P<0.018$). No statistically significant positive correlation was shown in comparison to MDA-LDL IgG ($P<0.046$), MDA-LDL IgM ($P<0.057$), HSA-MDA IgM ($P<0.411$), and IgG immunocomplexes ($P<0.406$).

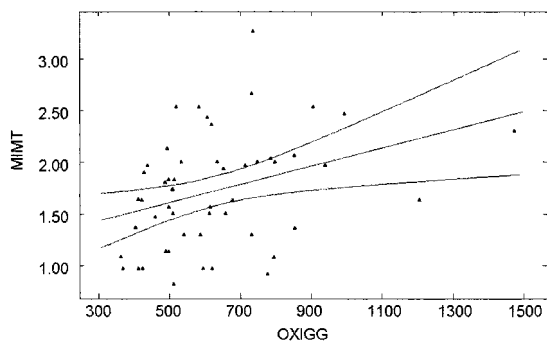


Figure 2. MIMT, expressed in millimeters, 6 months after surgery, comparing the IgG antibodies against oxidized LDL (OXIGG) in patients' serum at the time of surgery. The equation describing the regression line is $MIMT=1.2002+0.0009 \times$ oxidized LDL IgG ($r=0.34$; CI, 0.10 to 0.58; $P<0.012$; $n=52$).

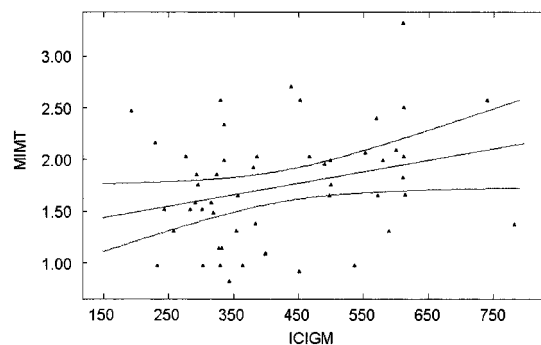


Figure 3. MIMT, expressed in millimeters, 6 months after surgery, comparing the IgM immunocomplexes (ICIGM) in patients' serum at the time of surgery. The equation describing the regression line is $MIMT=1.2901+0.0011 \times$ IgM immunocomplexes ($r=0.28$; CI, 0.03 to 0.53; $P<0.043$; $n=52$).

A significant positive correlation was shown between MIMT and IgM immunocomplexes ($P<0.043$) (Figure 3).

Discussion

Despite a large amount of research on the pathogenesis of restenosis, no clear causative factors are reported in the literature. Arterial wall trauma is considered the main cause of restenosis, but it is not sufficient to explain restenosis variability. In addition, no correlation exists between stenosis before surgery and restenosis at 6 months after the operation. Pauletto et al⁵ showed an abundance of smooth muscle cells and a scarcity of macrophages in the primary lesions of patients with abnormal development of intima after surgery.

We noted that echographic aspects and growth time of restenotic plaques differ from those of typical atherosclerotic plaques. We found a direct positive correlation between the altered immune response and IMT, the measurement of which is considered a valid method to evaluate atherosclerotic progression.⁶

In vivo LDL oxidation causes antigenic epitope formation, which elicits formation of an immune response. Among the observed modifications, transformation of lysine ϵ -amino groups into apoprotein B100 by MDA and the presence of autoantibodies against MDA-LDL are considered biological indices of LDL in vivo oxidation. Since MDA-lysine is the antigenic determinant of the immune reaction, the transformation into MDA of several proteins other than LDL could give rise to cross-reactions with MDA-LDL and to false-positive results. A lack of significant cross-reaction with HSA-MDA-derived LDL constituted the criterion for determining autoantibody specificity against LDL.⁷

The lag-phase duration depends on the content of LDL antioxidants. The peak time represents maximal oxidation and is strictly related to lag-phase duration and to propagation rate velocity.

A reduction in lag phase indicates higher LDL susceptibility to in vitro oxidation. However, this parameter does not provide any explanation in regard to in vivo oxidation. LDL modifications during oxidation consist mainly of the production of adducts among the apoprotein B100 and the aldehydes derived from lipid peroxidation. The structural change provokes such important modifications in the lipoprotein mole-

cule as to modify its antigenic characteristics and to evoke an antibody response.⁸

The presence of antibodies against oxidized LDL in the serum or plasma is thus considered a biological marker of in vivo oxidation.

Conclusion

Carotid restenosis is associated both with increased susceptibility of LDL to in vitro oxidation (increased lag phase) and with the production of antibodies against oxidized LDL, which proves in vivo oxidation. This is possibly due to the arterial wall hyperplastic response to surgery and to the altered immune response at the time of operation, as indicated by the correlation with IgM immunocomplexes.

These data may be a starting point in the development of a new treatment for the prevention of carotid restenosis, such as the use of antioxidant or even immunosuppressive drugs at the time of surgery.

References

1. Salonen JT, Yil-Herttuala S, Yamamoto R, Butler S, Korpela H, Salonen R, Nyyssonen K, Palinski W, Witztum JL. Autoantibody against oxidized LDL and progression of carotid atherosclerosis. *Lancet*. 1992;339:883-887.
2. Esterbauer H, Striegl G, Puhl H, Rothender M. Continuous monitoring of in vitro oxidation of human low-density lipoprotein. *Free Radic Res Commun*. 1989;6:65-67.
3. Chiesa R, Melissano G, Castellano R, Astore D, Marone EM, Grossi A, Maggi E, Finardi G, Casasco A, Bellomo G. In search of biological markers of high-risk carotid artery atherosclerotic plaque: enhanced LDL oxidation. *Ann Vasc Surg*. 1998;12:1-9.
4. O'Donnel TF, Callow AD, Scott G. Ultrasound characteristics of recurrent carotid disease: hypothesis explaining the low incidence of symptomatic recurrence. *J Vasc Surg*. 198;2:26-41.
5. Pauletto P, Pauletto P, Puato M, Faggini E, Santipolo N, Pagliara V, Zoleo M, Deriu GP, Grego F, Plebani M, Sartore S, Bon GB, Heymes C, Samuel JL, Pessina AC. Specific cellular features of atheroma associated with development of neointima after carotid endarterectomy: the Carotid Atherosclerosis and Restenosis Study. *Circulation*. 2000;102:771-778.
6. Zureik M, Touboul PJ, Bonithon-Kopp C, Courbon D, Berr C, Leroux C, Ducimetiere P. Cross-sectional and 4-year longitudinal associations between brachial pulse pressure and common carotid intima-media thickness in a general population. *Stroke*. 1999;30:550-555.
7. Weigand MA, Laipple A, Plaschke K, Eckstein HH, Martin E, Bardenheuer HJ. Concentration changes of malondialdehyde across the cerebral vascular bed and shedding of L-selectin during carotid endarterectomy. *Stroke*. 1999;30:306-311.
8. Steinberg D. Antioxidants in the prevention of human atherosclerosis: summary of the proceedings of a National Heart, Lung, and Blood Institute Workshop, September 5-6, 1991, Bethesda, Md. *Circulation*. 1992;85:2337-2344.