

Stroke

JOURNAL OF THE AMERICAN HEART ASSOCIATION

American Stroke
AssociationSM

A Division of American
Heart Association



Blood velocity in the middle cerebral artery and regional cerebral blood flow during carotid endarterectomy

JH Halsey, HA McDowell, S Gelmon and RB Morawetz

Stroke 1989;20;53-58

Stroke is published by the American Heart Association, 7272 Greenville Avenue, Dallas, TX 72514
Copyright © 1989 American Heart Association. All rights reserved. Print ISSN: 0039-2499. Online ISSN:
1524-4628

The online version of this article, along with updated information and services, is located on the World Wide Web at:

<http://stroke.ahajournals.org>

Subscriptions: Information about subscribing to *Stroke* is online at
<http://stroke.ahajournals.org/subscriptions/>

Permissions: Permissions & Rights Desk, Lippincott Williams & Wilkins, a division of Wolters Kluwer Health, 351 West Camden Street, Baltimore, MD 21202-2436. Phone: 410-528-4050. Fax: 410-528-8550. E-mail:
journalpermissions@lww.com

Reprints: Information about reprints can be found online at
<http://www.lww.com/reprints>

Blood Velocity in the Middle Cerebral Artery and Regional Cerebral Blood Flow During Carotid Endarterectomy

James H. Halsey, MD, Holt A. McDowell, MD,
Simon Gelmon, MD, and Richard B. Morawetz, MD

Blood flow velocity in the middle cerebral artery, determined by transcranial Doppler ultrasonography, was monitored during 31 carotid endarterectomies. Electroencephalogram (EEG) was also monitored, and regional cerebral blood flow (rCBF) was measured. The relation between rCBF and mean velocity was dependent on the rCBF level; the correlation was strong if rCBF was less than 20 ml/100 g/min but weak if rCBF was greater than that level. Ipsilateral EEG suppression was related to a rCBF threshold of 9 ml/100 g/min and to a mean velocity threshold of 15 cm/sec; the rCBF threshold was more specific for EEG change. Postischemic hyperemia was evident in measurements of mean velocity but not of rCBF. These disparities between mean velocity and rCBF seemed to be due to three factors: 1) disproportionately high mean velocity in patients with stenosis of the middle cerebral artery, 2) a nonlinear relation between mean velocity and rCBF, and 3) the anatomically different regions of the brain in which mean velocity and rCBF are measured. The velocity measurement appeared to be relatively more sensitive than rCBF to hemodynamic events in the corpus striatum and internal capsule. (*Stroke* 1989;20:53–58)

Transcranial Doppler ultrasonography (TCD) permits monitoring of the direction and velocity of blood flow in the horizontal (M1) segment of the middle cerebral artery (MCA) and other proximal branches of the circle of Willis.^{1–4} Because blood velocity is influenced by blood vessel diameter, there is uncertainty about its relation to cerebral blood flow. We address this problem by comparing MCA blood velocity with simultaneous measurements of regional cerebral blood flow (rCBF) during carotid endarterectomy.

Subjects and Methods

Thirty-one carotid endarterectomies were performed in 24 men and six women, all white, aged 48–81 years; one man underwent bilateral operations on separate occasions. The indications for surgery included a history of transient ischemic attacks or stroke and angiographic demonstration of >50% stenosis of the origin of the internal carotid artery.

Because of our interest in monitoring, high-risk patients (e.g., those with contralateral stenosis or occlusion, preexisting neurologic disability or other cardiovascular disorder, or advanced age) comprised a relatively larger proportion of the case material in our series than of the carotid surgical practice at our hospital.^{5–8} The operations were performed under general anesthesia with isoflurane. The clamp time varied from 8 to 29 minutes; a shunt was used in one case. Those patients developing cerebral ischemia represented by ipsilateral electroencephalographic (EEG) suppression during surgery or clinical disability after surgery are listed in Table 1.

rCBF was measured by injecting xenon-133 into the common carotid artery while the external carotid artery was clamped a few minutes before, at, and a few minutes after the release of clamping of the internal carotid artery. To measure rCBF at clamping, xenon-133 was injected a few seconds before application of the clamp. Isotope clearance was monitored by a single uncollimated 2-in.-diameter NaI scintillation detector, and rCBF as milliliters per 100 grams brain per minute was determined from the slope of the first 2 minutes of clearance.^{6–9} Measurement of rCBF is dominated by the cortex of the cerebral convexity because of its proximity to the detector.¹⁰

EEG was monitored continuously from scalp electrodes placed according to the international

From the Departments of Neurology, Surgery, and Anesthesiology and the Stroke Research Center, The University of Alabama Medical Center, Birmingham, Alabama.

Supported in part by National Institutes of Health Grant NS 08802 and by the Gitenstein Foundation.

Address for correspondence: Dr. Halsey, Department of Neurology, University Station, Birmingham, AL 35294.

Received August 31, 1987; accepted July 6, 1988.

TABLE 1. Summary of Complicated Cases Among 31 Carotid Endarterectomies

| Case | rCBF (ml/100 g/min) | | | Velocity (cm/sec) | | | Clamping (min) | Complicating arterial lesion | Postoperative complication |
|------------------------------------|---------------------|----|-------|-------------------|----|-------|----------------------|---|----------------------------|
| | Before | At | After | Before | At | After | | | |
| <i>Ipsilateral EEG suppression</i> | | | | | | | | | |
| 1 | 27 | 6 | 29 | 24 | 0 | 35 | 4 to shunt, 15 total | Contralateral occlusion | 24-hr hemiparesis |
| 2* | 34 | 9 | 32 | 95 | 0 | 124 | 20 | Stenosis of opposite carotid and basilar arteries, both MCAs, both ACAs from right carotid artery | None |
| 3* | 22 | 7 | 39 | 66 | 0 | 104 | 9 | | Brainstem infarct |
| 4 | — | 8 | 32 | 60 | 0 | 132 | 17 | MCA stenosis | 24-hr hemiparesis |
| 5 | 32 | 9 | 20 | 20 | 14 | 14 | 18 | None | None |
| 6 | 18 | 7 | 16 | 26 | 9 | 18 | 22 | Contralateral occlusion | None |
| <i>No EEG change</i> | | | | | | | | | |
| 7 | 27 | 18 | 22 | 21 | 11 | 63 | 20 | Contralateral occlusion | Cerebral hemorrhage |
| 8 | 27 | 11 | 36 | 44 | 16 | 46 | 25 | Hemiparesis before surgery | Hemiplegia |

rCBF, regional cerebral blood flow; EEG, electroencephalogram; MCA, middle cerebral artery; ACA, anterior carotid artery. Time relative to clamping.

*Successive operations in same patient.

10-20 system. Arterial blood pressure was monitored via a radial artery catheter.

Blood velocity in the MCA was monitored with an EME TC 2-64 instrument (Überlingen, FRG), a range-gated pulsed Doppler system incorporating a frequency analyzer. The transducer operates at 2 MHz; the emitted power is 100 mW/cm². We used a modified prototype transducer that could be held in place in the temporal region with an elastic bandage. Only the M1 segment of the MCA is accessible by this technique.¹⁻⁴

Blood velocity in centimeters per second was computed as $V=0.039 \times F$, where F is the Doppler frequency shift in hertz. It is not possible to determine the angle between the ultrasonic beam and the direction of the artery. However, when this angle is <30°, as is the case with the MCA, the error, which is a function of the cosine of the angle, is <15%. This angle does not change during surgery while the transducer is fixed in place.

The range gating system permits selection of the depth (within approximately 5 mm) at which the measurement is made (the point of insonation). Inadvertent recording from the posterior cerebral artery can be excluded when the point of insonation is ≤ 45 mm from the temporal bone surface. In those patients in whom the point of insonation was deeper, 50 or 55 mm, recording from the posterior cerebral artery was suspected if blood velocity increased at clamping. If the point of insonation was 60 or 65 mm from the temporal bone surface, recording from the carotid siphon may have resulted. In such patients, blood velocity fell to 0 cm/sec at clamping even though the EEG was unaltered and rCBF remained satisfactory due to a competent circle of Willis and/or to leptomeningeal collateral blood flow. In our

series, the point of insonation of the MCA was 60 mm in one, 55 mm in three, 50 mm in 13, and 45 or 40 mm in 14 cases. The recording was limited to the MCA insofar as this was possible by these criteria.

In the continuously displayed velocity waveform there are several readily apparent indexes including the systolic peak (SV), end-diastolic nadir (DV), and the mean (MV) velocities; MV can be approximated as $MV=DV+(SV-DV)/3$. The instrument we used automatically computed and displayed a MV representing integration of the velocity waveform over several cardiac cycles based on a fast Fourier transformation (FFT) of the displayed pattern. MV has been the index most widely used in the clinical application of TCD. In our work there is a high correlation ($R=0.93$) between the FFT computation and the arithmetic calculation of MV; we limit our analysis to MV. Throughout the text, MV is usually computed by FFT, occasionally arithmetically approximated when editing of the display was necessary.

The velocity waveform was monitored continuously, and MV was manually recorded approximately once per minute (Figure 1). Each rCBF measurement was compared with the average of all MV measurements recorded in the 2-minute period during which rCBF was determined.

Results

Under 1-1.5% isoflurane, the EEG was usually characterized by medium-voltage 7-14-Hz activity with intermixed frontal 2-4-Hz slow waves. Before clamping, rCBF at this EEG level was 25-55 ml/100 g/min and MV was approximately 50% of that recorded preoperatively. A qualitatively deeper level of anesthesia was characterized by a "suppression-burst" EEG pattern, that is, periods of EEG silence

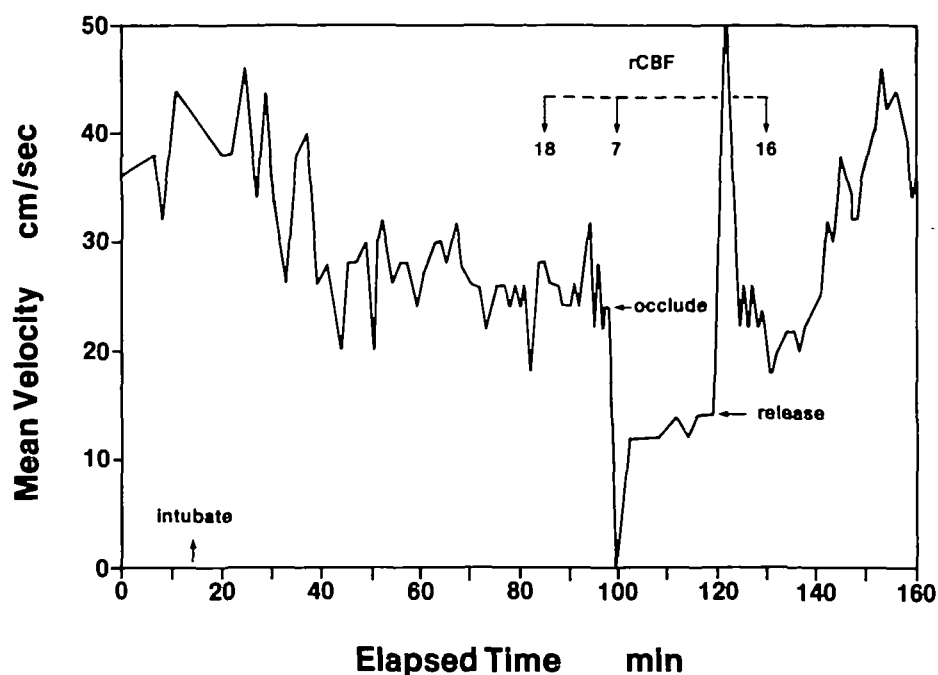


FIGURE 1. Continuous record of mean blood flow velocity in middle cerebral artery of Case 6 with contralateral internal carotid artery occlusion. Electroencephalogram was suppressed ipsilaterally during clamping (occlude). This case suffered no clinical disability. rCBF, regional cerebral blood flow in ml/100 g/min.

for 1–4 seconds alternating with variable-duration bursts of 6–12-Hz activity. This often occurred when rCBF before clamping was <20 ml/100 g/min and MV was <20 cm/sec. The ranges of rCBF and MV before, at, and after release of the clamping are summarized in Table 2.

In most cases, three pairs of rCBF-MV measurements were made: before clamping, at clamping, and after release. These revealed a wide scatter (correlation coefficient $R=0.47$, slope=1.04; Figure 2). Five of the highest MVs were recorded before clamping and after release in three patients with MCA stenosis. If these five MV measurements are excluded, the correlation of rCBF vs. MV is strengthened slightly ($R=0.52$) and the slope is diminished (slope=0.87). For all pairs of measurements at an rCBF of >20 ml/100 g/min there was little relation between rCBF and MV ($R=0.14$, slope=0.45). However, at an rCBF of <20 ml/100 g/min, the correlation was stronger ($R=0.66$, slope=2.14). Most of the measurements at an rCBF of >20 ml/100 g/min were made before or after release of clamping, while most of those below that level were made at clamping.

There was a similar variability between rCBF and MV at clamping (Figure 3). If rCBF remained >20 ml/100 g/min (eight patients), the relation was random ($R=0.04$, slope=0.10); below this level of

rCBF the correlation was stronger ($R=0.69$, slope=1.99). Thus, clamping did not alter the nature of the relation between rCBF and MV; clamping simply lowered them both. If rCBF was reduced to <12 ml/100 g/min, there was almost always at least momentary disappearance of the organized pulsatile velocity waveform displayed on the oscilloscope, though in some cases a pulsatile sound could still be heard on the audio output. In some cases the disappearance of the velocity waveform was sustained during clamping, whereas in other cases it gradually recovered, sometimes during the 2 minutes in which rCBF was measured, so that a MV of >0 ml/100 g/min could be calculated for this period.

In Case 4, the velocity waveform disappeared at clamping and subsequently returned, but the direction of blood flow in the proximal MCA intermittently reversed during clamping. The waveform was not pulsatile, and it varied widely from approximately 10 cm/sec in the normal direction to approximately 15 cm/sec in the reversed direction. This was thought to represent collateral blood supply via the convexity leptomeningeal anastomoses with distal anterior and posterior cerebral artery branches.

There was a strong relation between MV before clamping and that after release ($R=0.86$, slope=1.40; Figure 4). After release, MV tended to be higher

TABLE 2. Distribution of rCBF and Simultaneous Mean Blood Velocity in Middle Cerebral Artery for 31 Carotid Endarterectomies

| | rCBF (ml/100 g/min) | | | Mean velocity (cm/sec) | | |
|--------------------|---------------------|------|-------|------------------------|------|--------|
| | Before | At | After | Before | At | After |
| Range | 15–24 | 6–32 | 11–57 | 15–95 | 0–44 | 16–132 |
| Mean | 31 | 16 | 32 | 39 | 21 | 48 |
| Standard deviation | 9.1 | 6.5 | 11.2 | 18.4 | 11.7 | 30.0 |

rCBF, regional cerebral blood flow. Time relative to clamping.

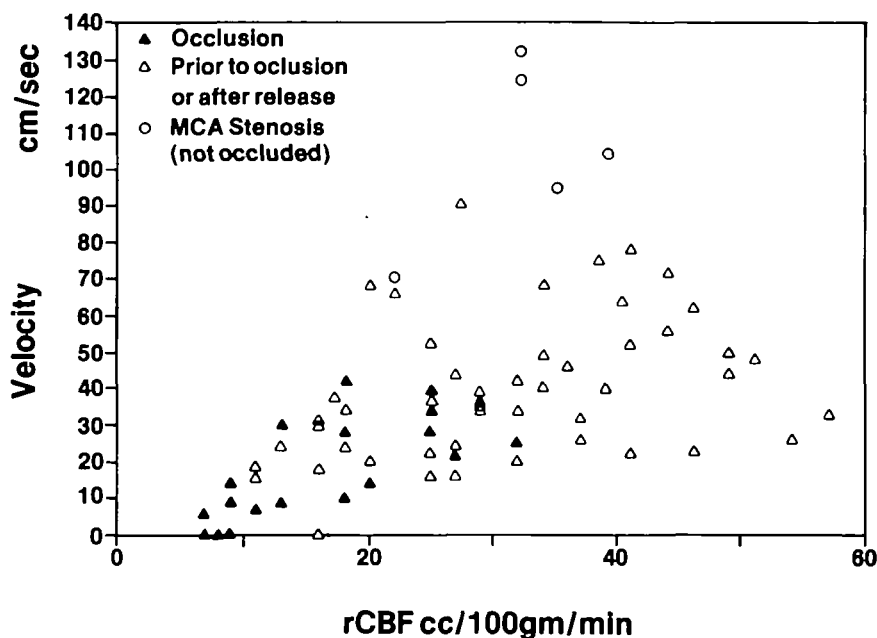


FIGURE 2. All paired measurements of regional cerebral blood flow (rCBF) and mean velocity in middle cerebral artery (MCA). Some scatter is due to MCA stenosis (open circles). Most of slope is due to measurements at rCBF of <20 ml/100 g/min. $R=0.47$, slope=1.04.

than that before clamping, suggesting mild postischemic hyperemia. There was also a relation between rCBF before clamping and that after release, but this relation was not so strong as that of MV ($R=0.58$, slope=0.72; Figure 5). rCBF after release tended to be lower than that before clamping, indicating that postrelease hyperemia was not occurring in the convexity cortex. In two cases (4 and 7), MV after release was disproportionately higher than that before clamping, though in neither case was there a comparable increase in rCBF.

In six endarterectomies there was focal suppression of EEG activity over the hemisphere ipsilateral

to the carotid artery being clamped (Cases 1-6). The rCBF threshold for EEG change was 9 ml/100 g/min; the MV threshold was 15 cm/sec. The absolute MV was more specific than the percent change in MV from before clamping. rCBF was more specific for EEG change than was MV. All six cases with rCBF at clamping of <9 ml/100 g/min had EEG suppression, while of the 10 cases with MV reduction to <15 cm/sec, there was no EEG change in four. In most of these six there was at least partial EEG recovery during clamping if it lasted for >12 minutes, usually associated with an increase in MV. If the EEG had not already recovered during clamp-

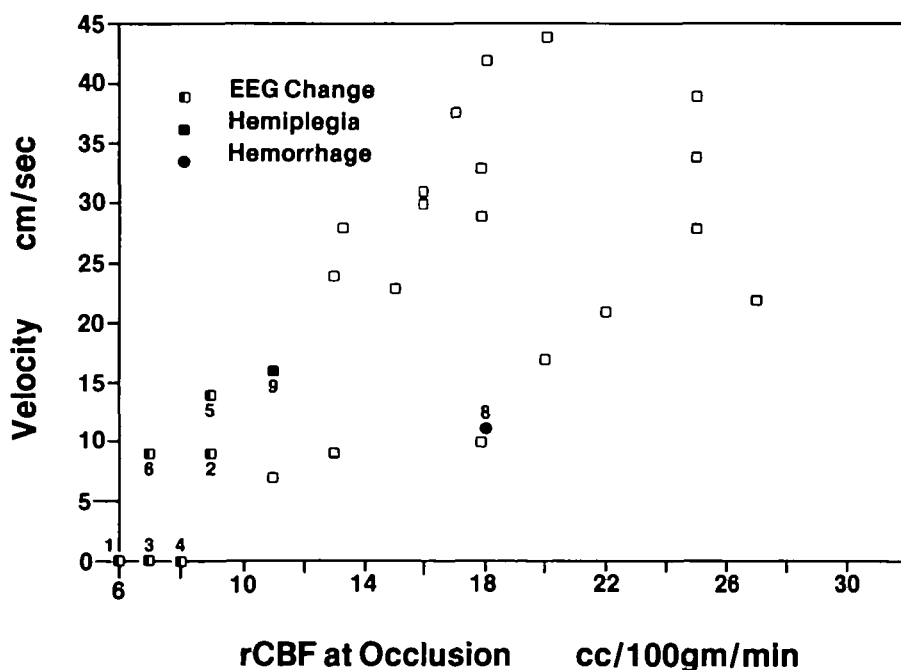


FIGURE 3. Paired regional cerebral blood flow (rCBF) and mean velocity measurements in middle cerebral artery measurements at clamping (occlusion). Slope is entirely due to measurements at rCBF of <20 ml/100 g/min. $R=0.69$, slope=1.99. Case numbers from Table 1. EEG, electroencephalogram.

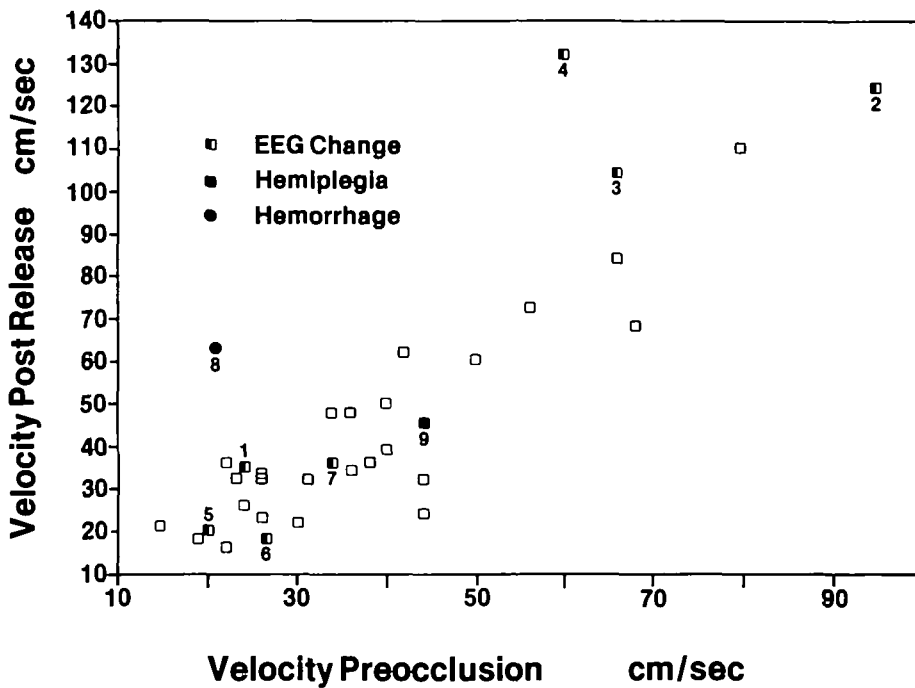


FIGURE 4. Comparison of mean velocity in middle cerebral artery before clamping (preocclusion) and after release. Post release velocity is systematically higher. $R=0.86$, slope=1.40. Case numbers from Table 1.

ing, it usually did so promptly upon release, as it did upon insertion of the shunt in the one patient in whom it was used.

Of these six cases, three patients recovered immediately without any postoperative clinical disability. In two there was minor hemiparesis and obtundation that cleared completely within 24 hours. One patient (Case 3) died of brainstem infarction, clinical signs of which were recognized approximately 12 hours after his initial recovery from anesthesia. He had undergone uncomplicated endarterectomy

on the opposite side (Case 2) approximately 2 weeks previously, with EEG suppression at that time also. His angiograms had demonstrated bilateral MCA stenosis, with both anterior cerebral arteries arising from the right carotid artery. At autopsy the infarction was found to be due to occlusion of a severely stenotic basilar artery.

In two cases the EEG was unimpaired though the velocity waveform disappeared intermittently during clamping. In both cases, rCBF was reduced substantially though not so severely as in the cases

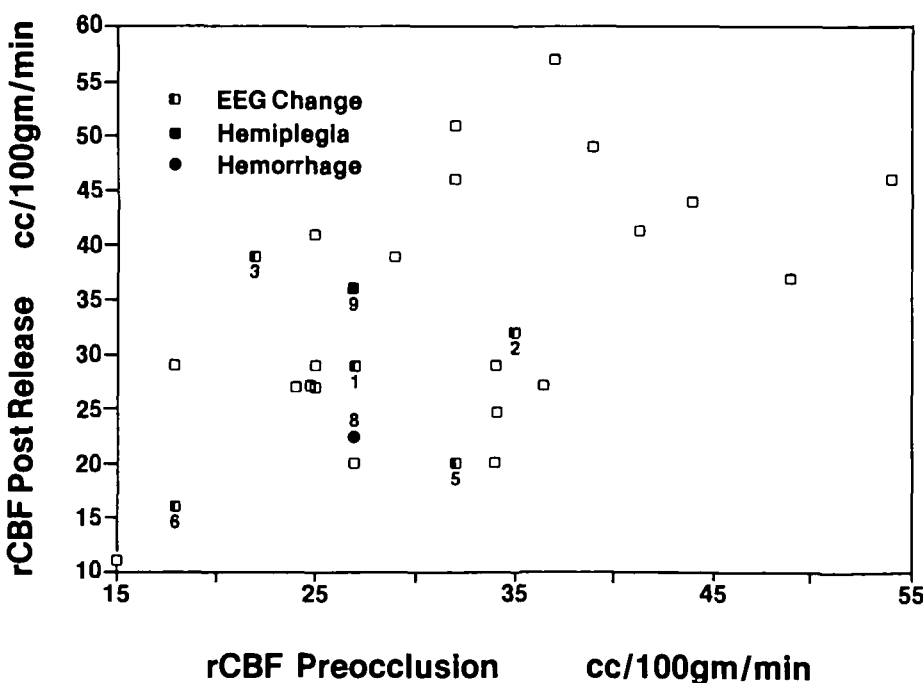


FIGURE 5. Comparison of regional cerebral blood flow (rCBF) before clamping (preocclusion) and after release. Post release values are slightly lower. $R=0.58$, slope=0.72. Case numbers from Table 1.

with EEG changes. Each case suffered a serious clinical complication. In Case 7, a putaminal hemorrhage developed 2 days postoperatively; this may have been heralded by extreme postrelease hyperemia detected by MV but not by rCBF. In Case 8 there was a preoperative mild hemiparesis, focally abnormal EEG, and computed tomographic (CT) demonstration of a lucency in the internal capsule; this patient suffered permanent hemiplegia, and postoperative CT scan demonstrated enlargement of the capsular lucency.

Discussion

There is a wide scatter when all pairs of rCBF and MV measurements are displayed at once (Figure 2). Three important factors contribute to this scatter. The first factor is the variation among patients in the diameter of the MCA.¹¹ If flow is constant, velocity varies as the reciprocal of the diameter squared. At its extreme, in angiographically recognizable MCA stenosis, this can be accounted for.¹² However, there are doubtless many cases of atherosclerotic MCA lesions on the anterior or posterior wall that cause the blood velocity to be high but which are not visible on the standard anteroposterior view angiogram. Secondly, the physiologic relation between blood flow and blood velocity is not linear. Earlier studies have demonstrated that blood flow is increased to above normal mostly as a function of blood volume, largely due to increased diameter of both intraparenchymal and extraparenchymal vessels, while blood flow is decreased to below normal mostly by reduction of velocity without much change in volume and, therefore, presumably in vascular diameter.^{13,14} Our observations of a steeper slope and greater correlation when rCBF is <20 ml/100 g/min than when it is above that level are compatible with those observations (Figures 2 and 3).

A third important factor is that rCBF and MV were measured in different regions of the brain. rCBF was measured predominantly in the cortical convexity while MV was measured in the M1 segment of the MCA at the base of the brain. This consideration may account for the better correspondence of the EEG changes with rCBF than with MV. It may also account for the apparent difference between the two measurements in sensitivity to reperfusion hyperemia (Figures 4 and 5). If this is a valid observation, the explanation may be that if ischemia is severe during clamping, there is relatively better collateral blood flow to the convexity cortex via leptomeningeal anastomoses with the anterior and posterior cerebral arteries than to the corpus striatum via the proximal MCA. Thus, if the ischemia is more severe in the corpus striatum, so too might be the postrelease hyperemia.

The apparently greater sensitivity of MV to hemodynamic events in the territory supplied by the lenticulostriate arteries is an important tentative conclusion of our study. Specific instances when

such events occurred without being reflected at the convexity include Case 7, in which the velocity waveform disappeared during clamping, though the EEG remained unaffected, with disproportionate postrelease (MV) hyperemia without comparable rCBF increase and postoperative putaminal hemorrhage; Case 8, with similar loss of velocity waveform without change in (the already abnormal) EEG and postoperative hemiplegia due to extension of the preexisting capsular infarct; and Case 4, in which the MCA flow direction reversed during clamping.

Because these anatomic differences between TCD and rCBF exist, one method cannot be validated by the other, nor should one really replace the other. The methods have different, complementary capabilities. In addition to its better demonstration of hemodynamic events at the base of the brain, an important strength of TCD is that it is continuous.

References

1. Aaslid RM, Markwalder T-M, Nornes H: Noninvasive transcranial Doppler ultrasound recording of flow velocity in basal cerebral arteries. *J Neurosurg* 1982;57:769-774
2. Lindegaard F, Bakke SJ, Grolimund P, Aaslid R, Huber P, Nornes H: Assessment of intracranial hemodynamics in carotid artery disease by transcranial Doppler ultrasound. *J Neurosurg* 1985;63:890-898
3. Wechsler L, Ropper A, Kistler JP: Transcranial Doppler in cerebrovascular disease. *Stroke* 1986;17:905-912
4. Bishop C, Powell S, Rutt D, Browne N: Transcranial Doppler measurement of middle cerebral artery blood flow velocity: A validation study. *Stroke* 1986;17:913-920
5. Cho I, Smullens SN, Streletz LJ, Fariello RG: The value of intraoperative EEG monitoring during carotid endarterectomy. *Ann Neurol* 1986;20:508-512
6. Morawetz RB, Zeiger HE, McDowell HA, McKay R, Varner P, Gelman S, Halsey JH: Correlation of cerebral blood flow and EEG during carotid endarterectomy (without shunting) and neurologic outcome. *Surgery* 1984;96:184-189
7. Sundt TM: The ischemic tolerance of neural tissue and the need for monitoring and selective shunting during carotid endarterectomy. *Stroke* 1983;14:93-98
8. Sundt TM, Sharbrough FW, Piepgras DG, Kearns TP, Messick JM, O'Fallon WM: Correlation of cerebral blood flow and electroencephalographic changes during carotid endarterectomy. *Mayo Clin Proc* 1981;56:533-543
9. Olesen J, Paulson DB, Lassen NA: Regional cerebral blood flow in man determined by the initial slope of the clearance of intra-arterially injected ¹³³Xe. *Stroke* 1971;2:519-540
10. McHenry LC, Jaffe ME, Goldberg HI: Regional cerebral blood flow measurement with small probes. *Neurology* 1969;19:1198-1206
11. Gabrielsen T, Greitz DT: Normal size of the internal carotid, middle cerebral, and anterior cerebral arteries. *Acta Radiol [Diagn]* (Stockh) 1970;10:1-10
12. Lindegaard K-F, Bakke SJ, Aaslid R, Nornes H: Doppler diagnosis of intracranial artery occlusive disorders. *J Neurol Neurosurg Psychiatry* 1986;49:510-518
13. Risberg J, Ancrì D, Ingvar DH: Regional cerebral blood volume changes related to blood flow variations. *Scand J Lab Clin Invest* 1968(suppl 102):11B
14. Harper AM, Rowan JD, Jennett WB: Oldendorf's non-diffusible indicator transit approach. *Scand J Lab Clin Invest* 1968(suppl 102):11B

KEY WORDS • cerebral blood flow • endarterectomy • ultrasonics