

# Stroke

American Stroke  
Association<sup>SM</sup>

JOURNAL OF THE AMERICAN HEART ASSOCIATION

A Division of American  
Heart Association



## **Sustained Bilateral Hemodynamic Benefit of Contralateral Carotid Endarterectomy in Patients With Symptomatic Internal Carotid Artery Occlusion**

D. R. Rutgers, C. J. M. Klijn, L. J. Kappelle, B. C. Eikelboom, A. C. van Huffelen and J. van der Grond

*Stroke* 2001;32:728-734

Stroke is published by the American Heart Association, 7272 Greenville Avenue, Dallas, TX 75214  
Copyright © 2001 American Heart Association. All rights reserved. Print ISSN: 0039-2499. Online  
ISSN: 1524-4628

The online version of this article, along with updated information and services, is located on the World Wide Web at:

<http://stroke.ahajournals.org/cgi/content/full/32/3/728>

Subscriptions: Information about subscribing to Stroke is online at  
<http://stroke.ahajournals.org/subscriptions/>

Permissions: Permissions & Rights Desk, Lippincott Williams & Wilkins, a division of Wolters Kluwer Health, 351 West Camden Street, Baltimore, MD 21202-2436. Phone: 410-528-4050. Fax: 410-528-8550. E-mail:  
[journalpermissions@lww.com](mailto:journalpermissions@lww.com)

Reprints: Information about reprints can be found online at  
<http://www.lww.com/reprints>

# Sustained Bilateral Hemodynamic Benefit of Contralateral Carotid Endarterectomy in Patients With Symptomatic Internal Carotid Artery Occlusion

D.R. Rutgers, MD; C.J.M. Klijn, MD; L.J. Kappelle, MD; B.C. Eikelboom, MD;  
A.C. van Huffelen, MD; J. van der Grond, PhD

**Background and Purpose**—We sought to investigate whether in patients with a symptomatic internal carotid artery (ICA) occlusion, endarterectomy of a severe stenosis of the contralateral carotid artery can establish long-term cerebral hemodynamic improvement.

**Methods**—Nineteen patients were studied on average 1 month before and 6 months after contralateral carotid endarterectomy (CEA). Volume flow in the main extracranial and intracranial arteries was measured with MR angiography. Collateral flow via the circle of Willis and the ophthalmic arteries was studied with MR angiography and transcranial Doppler sonography, respectively. Cerebral metabolism and CO<sub>2</sub> vasoreactivity were investigated with MR spectroscopy and transcranial Doppler sonography, respectively. Twelve nonoperated patients with a symptomatic ICA occlusion and contralateral ICA stenosis, who were matched for age and sex, served as control patients.

**Results**—In patients who underwent surgery, flow in the operated ICA increased significantly ( $P<0.05$ ) and flow in the basilar artery decreased significantly ( $P<0.01$ ) after CEA. On the occlusion side, mean flow in the middle cerebral artery increased significantly from 71 to 85 mL/min ( $P<0.05$ ) after CEA. The prevalence of collateral flow via the anterior communicating artery to the occlusion side increased significantly (47% before and 84% after CEA;  $P<0.05$ ), while the prevalence of reversed ophthalmic artery flow on the operation side decreased significantly (42% before and 5% after CEA;  $P<0.05$ ). In the hemisphere on the side of the ICA occlusion, lactate was no longer detected after CEA in 80% of operated patients, whereas it was no longer detected over time in 14% of nonoperated patients ( $P<0.05$ ). CO<sub>2</sub> reactivity increased significantly in operated patients in both hemispheres ( $P<0.01$ ).

**Conclusions**—Contralateral CEA in patients with a symptomatic ICA occlusion induces cerebral hemodynamic improvement not only on the side of surgery but also on the side of the ICA occlusion. (*Stroke*. 2001;32:728-734.)

**Key Words** carotid artery occlusion ■ carotid endarterectomy ■ magnetic resonance angiography ■ spectroscopy, nuclear, magnetic resonance ■ transcranial Doppler sonography

In patients with a symptomatic occlusion of the internal carotid artery (ICA), blood flow to the brain may be compromised.<sup>1</sup> When the contralateral ICA is also stenosed, cerebral hemodynamics can be even more disturbed, which may increase the risk of recurrent symptoms.<sup>2</sup> In these patients, carotid endarterectomy (CEA) of the contralateral ICA is often performed to improve collateral blood flow to the symptomatic hemisphere.<sup>3-8</sup> No randomized studies have evaluated the clinical effect of this operation. Its hemodynamic effects have been investigated in a number of studies<sup>9-14</sup>; however, these studies did not unequivocally demonstrate a hemodynamic benefit. In these studies, nonoperated control subjects were not investigated to exclude the possibility of natural hemody-

amic recovery,<sup>9-11,13,14</sup> few patients were investigated,<sup>14</sup> or patients who were asymptomatic with respect to the ICA occlusion were included.<sup>9,10,12,13</sup> Therefore, in patients with a symptomatic ICA occlusion, little is known about the hemodynamic consequences of endarterectomy of severe stenosis of the contralateral ICA.

The aim of our study was to investigate whether, in patients with a symptomatic ICA occlusion, CEA of severe stenosis of the contralateral ICA can establish long-term hemodynamic improvement. This was studied at 3 levels: (1) changes in volume flow in the main extracranial and intracranial arteries, (2) changes in collateral flow via the circle of Willis and the ophthalmic arteries (OphAs), and (3) changes in the end organ, the brain, as reflected in cerebral metabolism and vasoreactivity.

Received October 13, 2000; final revision received November 24, 2000; accepted November 24, 2000.

From the Departments of Radiology (D.R.R., J. van der G.), Neurology (C.J.M.K., L.J.K.), Vascular Surgery (B.C.E.), and Clinical Neurophysiology (A.C. van H.), University Medical Center Utrecht (University Hospital Utrecht, Medical Faculty Utrecht, and Wilhelmina Children's Hospital) (Netherlands).

Correspondence to D.R. Rutgers, MD, Department of Radiology, E01.132, University Medical Center Utrecht, Heidelberglaan 100, 3584 CX Utrecht, Netherlands. E-mail D.Rutgers@azu.nl

© 2001 American Heart Association, Inc.

Stroke is available at <http://www.strokeaha.org>

## Subjects and Methods

### Patients and Control Subjects

Between 1995 and 1998, 117 patients were referred to the Department of Neurology of our hospital because of an angiographically proven symptomatic ICA occlusion. In principle, all patients with a >70% stenosis of the ICA on the contralateral side were offered endarterectomy of the stenosed ICA. From these patients, we included 19 patients in the present study. Five patients were excluded because they refused operation, no follow-up examinations were available, or extracranial-intracranial bypass surgery was also performed. Patients were studied preoperatively and postoperatively with MR angiography (MRA), MR spectroscopy (MRS), and transcranial Doppler sonography (TCD). These investigations were performed on average 1 month before and 6 months after the operation (Table 1). Patients were operated on because they had a >70% stenosis of the contralateral ICA. However, it should be realized that at present there are no objective criteria to decide whether contralateral CEA should be performed in a patient with a symptomatic ICA occlusion.

CEA was performed under general anesthesia. A temporary intraluminal shunt was inserted if ischemic electroencephalographic changes occurred after cross-clamping of the carotid artery. Otherwise, endarterectomy was performed without an intraluminal shunt. Patency of the operated ICA was evaluated with Duplex sonography on average 3 months after the operation.

To assess whether hemodynamic changes occur when no CEA is performed, we investigated 12 patients with a symptomatic ICA occlusion who had a stenosis of the contralateral ICA that was not operated on. These patients were matched for age and sex. Some had a >70% ICA stenosis on the contralateral side, but contralateral CEA was not performed because they refused operation. Patients did not suffer from recurrent neurological deficits during follow-up and were studied with MR and TCD at referral and on average 6 months later (Table 1).

All patients suffered from transient or at most moderately disabling (modified Rankin Scale score<sup>15</sup> ≤3) neurological deficits in the supply territory of the ICA occlusion within 6 months before referral. Deficits included transient monocular blindness, hemispheric transient ischemic attacks (TIAs), or ischemic stroke. Two patients who were operated on also had cerebral ischemic symptoms on the side of the operated ICA (hemispheric TIA in 1 patient, minor stroke in 1 patient). Intra-arterial digital subtraction angiography was performed in all patients to confirm the occlusion of the ICA. The degree of lumen reduction of the stenosed ICA was assessed according to the criteria of the North American Symptomatic Carotid Endarterectomy Trial.<sup>16</sup> All patients were treated with antithrombotic medication, ie, low-dose aspirin in the majority of patients.

To obtain reference values for the quantitative volume flow and MRS measurements, 31 age- and sex-matched control subjects (mean±SD age, 58±12 years; 22 men, 9 women) were investigated. They were recruited from the departments of neurology and urology, where they were hospitalized for other than intracranial diseases. MRI did not show cerebral abnormalities in these subjects. In addition, 30 age- and sex-matched control subjects (mean±SD age, 59±10 years; 25 men, 5 women) were investigated to obtain reference values for the CO<sub>2</sub> reactivity measurements. These subjects were scheduled for implantation of an internal cardioverter defibrillator. None of them had a history of cerebral neurological complaints or atherosclerotic disease.

All patients and control subjects gave informed consent to participate in the study. The Human Research Committee of our hospital approved the study protocol.

### MR Angiography and MR Spectroscopy

Investigations were performed on a 1.5-T whole-body system (ACS-NT 15 model; Philips Medical Systems).

#### MR Angiography

On the basis of 2 localizer MRA slabs in the coronal and sagittal planes, a 2-dimensional phase-contrast (2D PC) slice was positioned perpendicular to the ICAs and the basilar artery (BA) at the level of

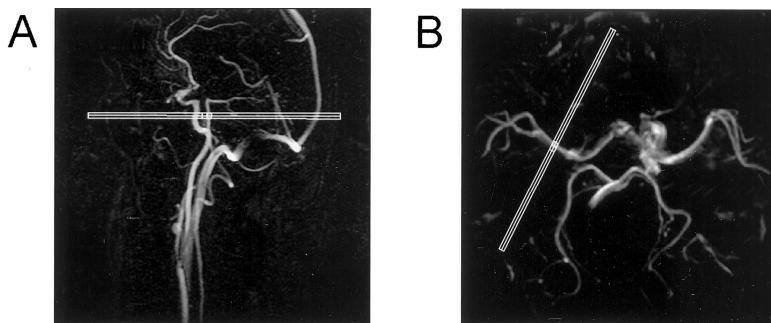
**TABLE 1. Baseline Characteristics, Degree of Stenosis of the Contralateral ICA, Time From Ischemic Event to Investigation, and Time Between Investigation and Operation in Patients With a Symptomatic ICA Occlusion Who Did or Did Not Undergo Contralateral CEA**

	CEA Patients	Nonoperated Patients
Baseline characteristics		
n	19	12
Age, mean±SD, y	62±7	63±12
Male/female, %	74/26	67/33
Ischemic event: retinal/hTIA/stroke, %	32/21/47	8/25/67
Modified Rankin score: 0/1/2/3, %	26/26/37/11	33/42/17/8
Degree of contralateral ICA stenosis, mean±SD, %	78±10	70±11
Time from ischemic event to investigation, mean±SD, d		
To preoperative/1st MR scan	84±70	120±38
To postoperative/2nd MR scan	302±74	312±50
To preoperative/1st TCD measurement	81±70	121±40
To postoperative/2nd TCD measurement	283±73	311±50
Time between investigation and CEA, mean±SD, d		
Preoperative MR scan/CEA	32±36	...
CEA/postoperative MR scan	187±25	...
Preoperative TCD measurement/CEA	34±36	...
CEA/postoperative TCD measurement	167±39	...

hTIA indicates hemispheric transient ischemic attack.

the skull base to measure volume flow in these vessels (nontriggered, repetition time [TR] 16 ms, echo time [TE] 9 ms, flip angle 7.5°, slice thickness 5 mm, field of view 250×250 mm, matrix size 256×256, 8 averages, velocity sensitivity 100 cm/s). PC MRA is considered to be a reliable method to quantify flow,<sup>17–19</sup> and the protocol in the present study has been previously developed and optimized both in vitro and in vivo.<sup>20,21</sup> Figure 1A shows the positioning of the 2D PC slice through the ICAs and BA. To measure flow in the middle cerebral arteries (MCAs), the circle of Willis was visualized by a 3-dimensional time-of-flight MRA scan (TR 31 ms, TE 6.9 ms, flip angle 20°, slice thickness 1.2 mm with an overlap of 0.6 mm, number of slices 50, 2 signals acquired), from which a reconstruction (256×256 matrix) was made in 3 orthogonal directions using a maximum intensity projection algorithm. On the basis of this reconstruction, a 2D PC slice was positioned perpendicular to each MCA to measure volume flow (nontriggered, TR 17 ms, TE 10 ms, flip angle 8°, slice thickness 5 mm, field of view 250×250 mm, matrix size 256×256, 24 averages, velocity sensitivity 70 cm/s). Figure 1B shows the positioning of the 2D PC slice through an MCA. Volume flow values in the ICAs, BA, and MCAs were calculated by integrating across manually drawn regions of interest that enclosed the vessel lumen closely.

To assess the direction of blood flow in the circle of Willis, 2 consecutive 2D PC measurements were performed. Previous studies have found PC MRA to be a reliable method to assess the direction of flow in the circle of Willis.<sup>22–24</sup> One of the 2D PC measurements was phase encoded in the anteroposterior direction and one in the left-right direction (TR 16 ms, TE 9.1 ms, flip angle 7.5°, slice thickness 13 mm, field of view 250×250 mm, matrix size 256×256, 8 averages, velocity sensitivity 40 cm/s). The 2D PC slices were positioned on the basis of the maximum intensity projection reconstruction of the circle of Willis. The images of the circle of Willis were evaluated independently by 2 investigators (D.R.R. and



**Figure 1.** Typical positioning of 2D PC MRA slices to measure flow in the ICAs, BA, and MCAs in a patient with an occlusion of the right ICA and a stenosis of the left ICA. A, Sagittal localizer MRA image illustrating the positioning of a 2D PC MRA slice through the ICAs and BA (anterior, left; posterior, right). B, Maximum intensity projection of a 3D time-of-flight MRA scan of the circle of Willis illustrating the positioning of a 2D PC MRA slice through the main stem of the right MCA (anterior, above; posterior, below).

C.J.M.K.) to assess the direction of blood flow in the A1 segment of the anterior cerebral artery and in the posterior communicating artery (PCoA), both on the side of the ICA occlusion. If blood flow in the A1 segment or PCoA was directed toward the ICA occlusion, it was categorized as collateral flow. Collateral flow in the A1 segment was considered to indicate the presence of collateral flow via the anterior communicating artery (ACoA). Discrepancies between the 2 investigators were reevaluated in a consensus meeting.

### <sup>1</sup>H MR Spectroscopy

MRS was performed with a single-voxel technique (spin-echo point resolved spectroscopy, TR 2000 ms, TE 136 ms, 2000 Hz spectral width, 2048 time domain data points, 64 signals acquired). On the basis of a transaxial T2-weighted image (spin-echo sequence, TR 2000 ms, TE 20/100 ms), a volume of interest was placed in the centrum semiovale, where it contained primarily white matter. Typical dimensions of the volume of interest were 70 mm in the anteroposterior direction, 35 mm in the left-right direction, and 15 mm in the craniocaudal direction. Inclusion of hyperintensities, edema, or subcutaneous fat was avoided. Both hemispheres were investigated. Water suppression was performed by selective excitation (60 Hz bandwidth), followed by a spoiler gradient. After zero-filling of the time-domain data points to 4096 data points, gaussian multiplication of 5 Hz, exponential multiplication of -4 Hz, Fourier transformation, and baseline correction, the *N*-acetyl-aspartate (NAA) (referenced at 2.01 ppm), total choline, total creatine, and lactate peaks were identified by their chemical shifts. To distinguish lactate resonances from lipid resonances at a TE of 136 ms, lactate was defined as an inverted resonance at 1.33 ppm with a signal-to-noise ratio >2 and a clearly identifiable 7-Hz J coupling. Because no absolute metabolic concentrations could be measured, peak heights were expressed as metabolic ratios for each volume of interest. Peak heights were assessed on an independent work station that required user intervention. Lactate was expressed as a dichotomous variable,<sup>25</sup> ie, present or not.

### Transcranial Doppler Sonography

TCD investigations were performed with a Multi-Dop X device (DWL). A 4-MHz Doppler probe was used to assess the direction of blood flow in the OphAs. Blood flow was categorized as retrograde flow if it was directed toward the ipsilateral ICA. Vasoreactivity in response to CO<sub>2</sub> administration was measured in the MCAs with a 2-MHz Doppler probe. After a 2-minute baseline period, patients inhaled a gas mixture of 5% CO<sub>2</sub> and 95% O<sub>2</sub> (carbogen) for the next 2 minutes. The carbogen was inhaled through a mouthpiece connected to a respiratory balloon, while a nose clip ensured proper inhalation. The CO<sub>2</sub> content of the breathing gas was monitored continuously with an infrared gas analyzer. A spectral TCD recording of 5 seconds was made after 1 minute during the baseline period and after 1.5 minutes of carbogen inhalation. The CO<sub>2</sub> reactivity was expressed as the relative change in blood flow velocity (BFV) in the MCA after 1.5 minutes of carbogen inhalation, according to the following formula:  $[(BFV_{CO_2} - BFV_{baseline}) / BFV_{baseline}] \times 100\%$ . The mean of the maximal BFV values during the spectral TCD recordings was used in this calculation.

### Statistical Analysis

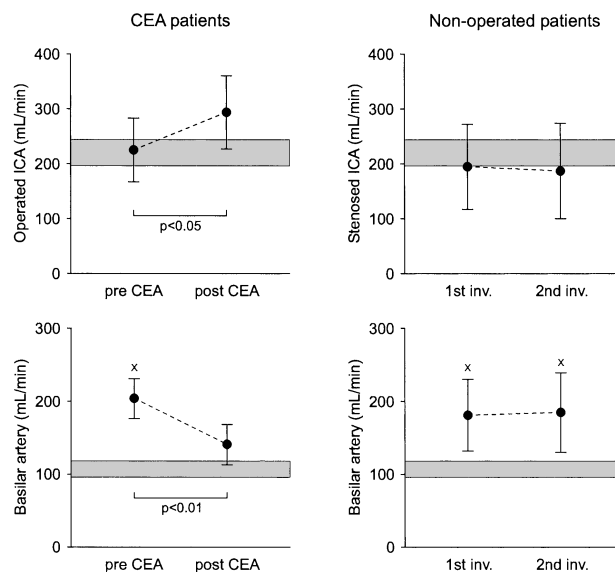
To compare baseline characteristics between operated and nonoperated patients, Student's *t* test or the  $\chi^2$  test was used. ANOVA with Dunnett's post hoc analysis was used to compare quantitative volume flow in the extracranial and intracranial arteries, metabolic ratios, and CO<sub>2</sub> reactivity between control subjects and operated or nonoperated patients. We made no direct comparison between operated and nonoperated patients because we included nonoperated patients primarily to assess whether hemodynamic changes could occur when no surgical intervention was performed.

In operated patients, differences in quantitative volume flow, metabolic ratios, and CO<sub>2</sub> reactivity between the preoperative and postoperative investigations were analyzed with Student's paired *t* test, while differences in prevalence of collateral flow and lactate were analyzed with the McNemar test for paired proportions. Similarly, differences between the first and second investigations in nonoperated patients were analyzed.

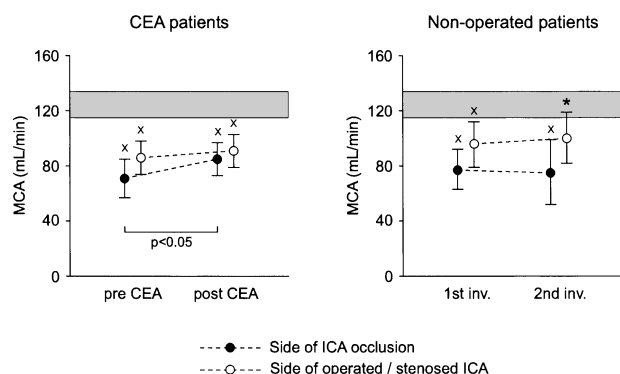
A *P* value <0.05 was considered statistically significant.

### Results

Type of ischemic event, degree of handicap, and time interval between the ischemic event and the various investigations did not differ significantly between operated and nonoperated patients



**Figure 2.** Volume flow (mean, 95% CI) in the contralateral operated or stenosed ICA (top row) and BA (bottom row) in patients with a symptomatic ICA occlusion who did or did not undergo contralateral CEA. The 95% CI of control subjects (ICA: mean, 220 mL/min; 95% CI, 196 to 244 mL/min; BA: mean, 107 mL/min; 95% CI, 96 to 118 mL/min) is shown in gray. Inv indicates investigation.  $xP < 0.01$ , patients vs control subjects (Dunnett's post hoc analysis after ANOVA).



**Figure 3.** Volume flow (mean, 95% CI) in the MCA in patients with a symptomatic occlusion of the ICA who did or did not undergo contralateral CEA. The 95% CI of control subjects (mean, 124 mL/min; 95% CI, 115 to 134 mL/min) is shown in gray. Inv indicates investigation.  $xP < 0.01$ ,  $*P < 0.05$ , patients vs control subjects (Dunnett’s post hoc analysis after ANOVA).

(Table 1). Two operated patients experienced recurrent hemispheric TIAs in the hemisphere ipsilateral to the ICA occlusion between the operation and the postoperative MR/TCD investigation. Postoperative Duplex investigation showed restenosis (>70%) of the operated ICA in another 2 operated patients.

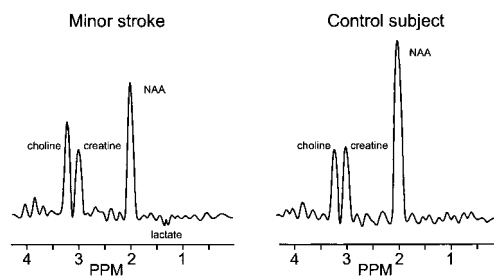
**Quantitative Volume Flow in Extracranial and Intracranial Arteries**

Figure 2 shows the time course of quantitative volume flow in the stenosed ICA and the BA. In operated patients, flow in the stenosed ICA increased significantly after CEA ( $P < 0.05$ ). Flow in the BA, which was preoperatively higher than in control subjects ( $P < 0.01$ ), decreased after CEA ( $P < 0.01$ ). In nonoperated patients, flow in the stenosed ICA and the BA did not change significantly over time. Flow in the BA was higher than in control subjects in both the first and second investigations ( $P < 0.01$ ).

Figure 3 shows the longitudinal changes of MCA flow in both patient groups. In operated patients, flow in the MCAs was lower than in control subjects, both preoperatively and postoperatively ( $P < 0.01$ ). On the side of the ICA occlusion, MCA flow increased after CEA ( $P < 0.05$ ), while we did not observe a significant change on the operation side. In nonoperated patients, flow in the MCAs did not change significantly over time. In these patients, MCA flow on both sides was significantly lower than in control subjects in both investigations.

**Collateral Flow**

In operated patients, the proportion of patients with collateral flow via the ACoA increased from 47% before to 84% after



**Figure 4.** Preoperative proton MRS spectrum of normal-appearing white matter in the hemisphere on the side of the occluded ICA in a patient with a symptomatic ICA occlusion who had a minor stroke (left). A spectrum from a control subject is shown on the right.

CEA ( $P < 0.05$ ). The proportion of patients with collateral flow via the PCoA did not change significantly (42% before and 26% after CEA). In nonoperated patients, we did not observe significant changes in the proportion of patients with collateral flow via the ACoA (33% before and 33% after CEA) or via the PCoA (8% before and 42% after CEA).

The proportion of patients with retrograde flow via the OphA on the side of the ICA occlusion did not change significantly in operated patients (Table 2). However, on the side of the operation the proportion of patients with retrograde flow in the OphA decreased after CEA ( $P < 0.05$ ). In nonoperated patients, there were no significant changes observed in the proportion of patients with retrograde flow via the OphAs.

**Cerebral Metabolism and CO<sub>2</sub> Reactivity**

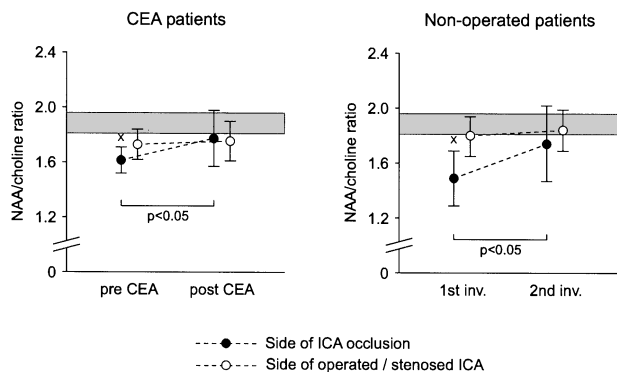
Figure 4 shows a typical preoperative <sup>1</sup>H MRS spectrum of normal-appearing white matter in a patient with a symptomatic ICA occlusion who had a minor stroke, as well as a spectrum from a control subject. Figure 5 shows the longitudinal changes of the NAA/choline ratios in both patient groups. In operated patients, the preoperative NAA/choline ratio in the hemisphere on the side of the ICA occlusion was lower than in control subjects ( $P < 0.01$ ). After CEA, this ratio increased ( $P < 0.05$ ), reaching control values. On the operation side, the NAA/choline ratio did not differ from that of control subjects and did not change after CEA. In nonoperated patients, the time course of the NAA/choline ratio on the side of the ICA occlusion and on the side of the stenosed ICA showed changes similar to those observed in operated patients.

Preoperatively, lactate was detected in 10 of 19 operated patients in the hemisphere on the side of the ICA occlusion.

**TABLE 2. Retrograde Flow in the OphAs in Patients With a Symptomatic ICA Occlusion Who Did or Did Not Undergo Contralateral CEA**

Retrograde Flow in OphA, % of Patients	CEA Patients (n=19)		Nonoperated Patients (n=12)	
	Before CEA	After CEA	1st Inv	2nd Inv
Side of ICA occlusion	79	63	92	83
Side of operated/stenosed ICA	42	5*	17	17

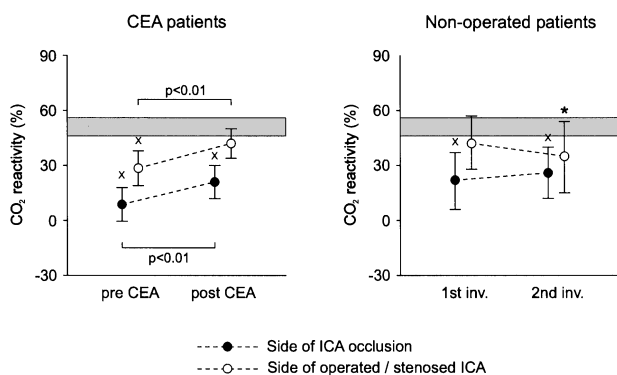
Inv indicates investigation.  
\* $P < 0.05$ , vs preoperative investigation.



**Figure 5.** NAA/choline ratio (mean, 95% CI) in patients with a symptomatic occlusion of the ICA who did or did not undergo contralateral CEA. The 95% CI of control subjects (mean, 1.89; 95% CI, 1.81 to 1.96) is shown in gray. Inv indicates investigation.  $xP < 0.01$  patients vs control subjects (Dunnett's post hoc analysis after ANOVA).

In 80% of these patients, lactate was no longer visible after CEA. This proportion was significantly higher than the proportion of nonoperated patients in whom lactate was no longer visible over time ( $P < 0.05$ ): in only 1 of the 7 nonoperated patients in whom lactate was detected in the first investigation was lactate no longer detectable in the second investigation.

Figure 6 shows the longitudinal changes of cerebral  $\text{CO}_2$  reactivity in both patient groups. In operated patients, preoperative  $\text{CO}_2$  reactivity on the side of the ICA occlusion was lower than in control subjects ( $P < 0.01$ ). After CEA,  $\text{CO}_2$  reactivity increased ( $P < 0.01$ ) but was still lower than in control subjects ( $P < 0.01$ ). On the side of the operated ICA, preoperative  $\text{CO}_2$  reactivity was lower than in control subjects ( $P < 0.01$ ). After CEA,  $\text{CO}_2$  reactivity increased ( $P < 0.01$ ) and no longer differed significantly from that of control subjects. In nonoperated patients,  $\text{CO}_2$  reactivity on the side of the ICA occlusion was lower than in control subjects in both the first and second investigations ( $P < 0.01$ ) and did not change significantly over time. On the side of the stenosed ICA,  $\text{CO}_2$  reactivity was lower in the second investigation than in



**Figure 6.**  $\text{CO}_2$  reactivity (mean, 95% CI) in patients with a symptomatic occlusion of the ICA who did or did not undergo contralateral CEA. The 95% CI of control subjects (mean, 51%; 95% CI, 46% to 56%) is shown in gray. Inv indicates investigation.  $xP < 0.01$ ,  $*P < 0.05$ , patients vs control subjects (Dunnett's post hoc analysis after ANOVA).

control subjects ( $P < 0.05$ ), and there was no significant change over time.

## Discussion

In the present study we investigated long-term hemodynamic changes in patients with a symptomatic ICA occlusion who did or did not undergo CEA of a severe stenosis of the contralateral ICA.

In the extracranial arteries, contralateral CEA resulted in redistribution of blood flow to the brain, as shown by an increase of flow in the operated ICA and a decrease of flow in the BA. Apparently, the contribution of BA flow to blood supply to the brain becomes less important if the contribution of the contralateral, stenosed ICA becomes more important. This is in accordance with a previous study.<sup>26</sup> In the circle of Willis, which is considered the primary collateral pathway in patients with an ICA occlusion,<sup>1</sup> we found that collateral flow via the ACoA to the side of the ICA occlusion increased. Most likely, this was caused by an increase of cerebral perfusion pressure on the operation side, which is expected to result from contralateral CEA. We assume that the increase of collateral flow via the ACoA accounted for the improvement of MCA flow on the side of the ICA occlusion. In the OphA on the side of the ICA occlusion, which is considered a secondary collateral in patients with an ICA occlusion,<sup>1</sup> we found no decrease of the prevalence of retrograde flow. This suggests that blood flow to the respective hemisphere may still have been relatively low after CEA, despite the improvement of collateral ACoA flow and the presumed increase of cerebral perfusion pressure. In addition to the circle of Willis and the ophthalmic artery, other pathways may provide collateral blood flow in patients with a symptomatic ICA occlusion. For example, additional anastomoses between the external and the internal carotid artery or leptomeningeal collaterals may be important. However, to study the collateral development in these relatively small anastomoses, invasive investigation by means of intra-arterial digital subtraction angiography rather than TCD or MRA may be the appropriate method.

At the level of the end organ, the brain, we found that the change over time of the NAA/choline ratios was comparable in operated and nonoperated patients. In  $^1\text{H}$  MRS of the brain, the NAA peak is generally regarded as indicative of the amount of functioning neurons because it is found almost exclusively in these cells.<sup>27</sup> The choline peak originates from choline, phosphocholine, and glycerolphosphocholine, which are involved in membrane metabolism.<sup>28</sup> A low NAA/choline ratio, which may indicate neuronal damage, has been associated with cerebral hypoperfusion.<sup>29</sup> The finding that NAA/choline ratios changed similarly over time in operated and nonoperated patients indicates that improvement of a low NAA/choline ratio takes place irrespective of whether contralateral CEA is performed. We speculate that in both patient groups a low NAA/choline ratio reflected metabolic changes that were induced by the initial ischemic event. These changes may not necessarily be related to alterations in perfusion pressure but may also have been caused by other factors such as microembolic damage. As opposed to nonoperated patients, operated patients showed a significant de-

crease of the prevalence of lactate in the hemisphere on the side of the ICA occlusion. If the presence of lactate is associated with low cerebral flow, as has been hypothesized,<sup>30,31</sup> this suggests that cerebral blood supply improved in patients in whom contralateral CEA was performed. Although flow alteration is a plausible explanation for the change in lactate, it should be emphasized that the presence of lactate may also be caused by macrophage activity.<sup>32,33</sup>

CO<sub>2</sub> reactivity on the side of the ICA occlusion was low in the preoperative investigation of operated patients and the first investigation of nonoperated patients. In occlusive carotid artery disease, distal cerebral arteries and arterioles may dilate to maintain cerebral blood flow.<sup>34</sup> As a result, the reserve capacity of these vessels to dilate is reduced. This is reflected in a low vasoreactivity in response to CO<sub>2</sub> administration. We found that CO<sub>2</sub> reactivity improved significantly in operated patients on the side of the ICA occlusion. This implies that blood flow to the respective hemisphere increased after CEA, which is in accordance with our quantitative flow and collateral flow measurements. Similar results on the effect of contralateral CEA on vasoreactivity have been found previously.<sup>11–13</sup> However, these studies also included patients with asymptomatic ICA occlusions. In these patients, cerebral hemodynamics may be different than in patients with symptomatic ICA occlusions.<sup>12,35,36</sup> In operated patients, CO<sub>2</sub> reactivity increased in the hemisphere on the side of the operation. This is primarily expected from contralateral CEA and is in agreement with data from the literature.<sup>13,37–39</sup> The bilateral improvement of cerebral vasoreactivity that we found in operated patients may be an important effect of contralateral CEA because this could be related to a lower risk of recurrent cerebral ischemia.<sup>40,41</sup> It should be noted that the difference in time course of CO<sub>2</sub> reactivity between operated and nonoperated patients may partly be explained by the fact that reactivity was initially lowest in operated patients; postoperative increase of CO<sub>2</sub> reactivity may be more pronounced in patients with low CO<sub>2</sub> reactivity.<sup>13,37</sup>

It should be realized that a comparison between our patient groups is complicated because all patients with a >70% contralateral ICA stenosis were offered CEA and no randomization was performed. Although the mean degree of contralateral ICA stenosis was ≥70% in both patient groups, as a consequence of our study design all operated patients had a >70% contralateral ICA stenosis, whereas many nonoperated patients had a <70% contralateral ICA stenosis. In addition, in nonoperated patients the first investigation was performed some time later than in operated patients, which may have accounted for hemodynamic differences.<sup>42</sup> In addition, 2 operated patients had symptoms on the contralateral side as opposed to nonoperated patients. Nevertheless, the inclusion of nonoperated patients is necessary to assess whether hemodynamic changes may occur in the absence of contralateral CEA. We found that 2 operated patients had recurrent symptoms and another 2 patients had restenosis of the operated ICA. Although these patients may be considered a different patient group with respect to the development of hemodynamic parameters, they are as much a result of our patient study as those in whom CEA was performed success-

fully without recurrent symptoms. We could not assess when the postoperative hemodynamic changes took place because we did not examine our patients multiple times after operation. However, our purpose was to investigate relatively long-term changes since it is likely that only lasting changes may account for possible beneficial effects on mortality and morbidity.

In summary, contralateral CEA in patients with a symptomatic ICA occlusion leads to hemodynamic improvement not only on the side of the operated ICA, as shown by an increase of cerebral CO<sub>2</sub> reactivity, but also on the side of the ICA occlusion, as demonstrated by an increase of MCA flow, an increase of collateral flow via the ACoA to the occlusion side, a decrease of the proportion of patients with hemispheric lactate, and an increase of cerebral CO<sub>2</sub> reactivity. On the basis of these results, we conclude that in patients with a symptomatic ICA occlusion, endarterectomy of a severe stenosis of the contralateral carotid artery is advisable from a hemodynamic point of view. To what extent this reduces long-term morbidity and mortality still must be elucidated.

### Acknowledgments

This study was supported by the Netherlands Organization for Scientific Research (NWO) (grant 920-03-091) (Dr Rutgers) and by the Netherlands Heart Foundation (grant 94.085) (Dr Klijn).

### References

1. Powers WJ. Cerebral hemodynamics in ischemic cerebrovascular disease. *Ann Neurol*. 1991;29:231–240.
2. Klijn CJM, Kappelle LJ, Tulleken CAF, van Gijn J. Symptomatic carotid artery occlusion: a reappraisal of hemodynamic factors. *Stroke*. 1997;28:2084–2093.
3. Hammacher ER, Eikelboom BC, Bast TJ, De Geest R, Vermeulen FE. Surgical treatment of patients with a carotid artery occlusion and a contralateral stenosis. *J Cardiovasc Surg*. 1984;25:513–517.
4. Mackey WC, O'Donnell TJJ, Callow AD. Carotid endarterectomy contralateral to an occluded carotid artery: perioperative risk and late results. *J Vasc Surg*. 1990;11:778–783.
5. Mattos MA, Barkmeier LD, Hodgson KJ, Ramsey DE, Sumner DS. Internal carotid artery occlusion: operative risks and long-term stroke rates after contralateral carotid endarterectomy. *Surgery*. 1992;112:670–679.
6. Jacobowitz GR, Adelman MA, Riles TS, Lamparello PJ, Imparato AM. Long-term follow-up of patients undergoing carotid endarterectomy in the presence of a contralateral occlusion. *Am J Surg*. 1995;170:165–167.
7. Ballotta E, Da Giau G, Guerra M. Carotid endarterectomy and contralateral internal carotid artery occlusion: perioperative risks and long-term stroke and survival rates. *Surgery*. 1998;123:234–240.
8. AbuRahma AF, Robinson P, Holt SM, Herzog TA, Mowery NT. Perioperative and late stroke rates of carotid endarterectomy contralateral to carotid artery occlusion: results from a randomized trial. *Stroke*. 2000;31:1566–1571.
9. Gee W, McDonald KM, Kaupp HA, Celani VJ, Bast RG. Carotid stenosis plus occlusion: endarterectomy or bypass? *Arch Surg*. 1980;115:183–187.
10. Cikrit DF, Burt RW, Dalsing MC, Lalka SG, Sawchuk AP, Waymire B, Witt RM. Acetazolamide enhanced single photon emission computed tomography (SPECT) evaluation of cerebral perfusion before and after carotid endarterectomy. *J Vasc Surg*. 1992;15:747–753.
11. Markus HS, Harrison MJ, Adiseshiah M. Carotid endarterectomy improves haemodynamics on the contralateral side: implications for operating contralateral to an occluded carotid artery. *Br J Surg*. 1993;80:170–172.
12. Widder B, Kleiser B, Krapf H. Course of cerebrovascular reactivity in patients with carotid artery occlusions. *Stroke*. 1994;25:1963–1967.
13. Visser GH, van Huffelen AC, Wieneke GH, Eikelboom BC. Bilateral increase in CO<sub>2</sub> reactivity after unilateral carotid endarterectomy. *Stroke*. 1997;28:899–905.

72914. Kluytmans M, Van der Grond J, Eikelboom BC, Viergever MA. Long-term hemodynamic effects of carotid endarterectomy. *Stroke*. 1998;29:1567-1572.
15. Bamford JM, Sandercock PAG, Warlow CP, Slattery J. Interobserver agreement for the assessment of handicap in stroke patients. *Stroke*. 1989;20:828.
  16. Fox AJ. How to measure carotid stenosis. *Radiology*. 1993;186:316-318.
  17. Spritzer CE, Pelc NJ, Lee JN, Evans AJ, Sostman HD, Riederer SJ. Rapid MR imaging of blood flow with a phase-sensitive, limited-flip-angle, gradient recalled pulse sequence: preliminary experience. *Radiology*. 1990;176:255-262.
  18. Enzmann DR, Marks MP, Pelc NJ. Comparison of cerebral artery blood flow measurements with gated cine and ungated phase-contrast techniques. *J Magn Reson Imaging*. 1993;3:705-712.
  19. Korosec FR, Turski PA. Velocity and volume flow rate measurements using phase contrast magnetic resonance imaging. *Int J Neuroradiol*. 1997;3:293-318.
  20. Bakker CJG, Kouwenhoven M, Hartkamp MJ, Hoogeveen RM, Mali WPTM. Accuracy and precision of time-averaged flow as measured by non-triggered 2D phase-contrast MR angiography: a phantom evaluation. *Magn Reson Imaging*. 1995;13:959-965.
  21. Bakker CJG, Hartkamp MJ, Mali WPTM. Measuring blood flow by nontriggered 2D phase contrast MR angiography. *Magn Reson Imaging*. 1996;14:609-614.
  22. Ross MR, Pelc NJ, Enzmann DR. Qualitative phase contrast MRA in the normal and abnormal circle of Willis. *AJNR Am J Neuroradiol*. 1993;14:19-25.
  23. Pernicone JR, Siebert JE, Laird TA, Rosenbaum TL, Potchen EJ. Determination of blood flow direction using velocity-phase image display with 3-D phase-contrast MR angiography. *AJNR Am J Neuroradiol*. 1992;13:1435-1438.
  24. Miralles M, Dolz JL, Cotillas J, Aldoma J, Santiso MA, Gimenez A, Capdevila A, Cairols MA. The role of the circle of Willis in carotid occlusion: assessment with phase contrast MR angiography and transcranial duplex. *Eur J Vasc Endovasc Surg*. 1995;10:424-430.
  25. Wardlaw JM, Marshall I, Wild J, Dennis MS, Cannon J, Lewis SC. Studies of acute ischemic stroke with proton magnetic resonance spectroscopy: relation between time from onset, neurological deficit, metabolite abnormalities in the infarct, blood flow, and clinical outcome. *Stroke*. 1998;29:1618-1624.
  26. van Everdingen KJ, Klijn CJM, Kappelle LJ, Mali WPTM, Van der Grond J. MRA flow quantification in patients with a symptomatic internal carotid artery occlusion. *Stroke*. 1997;28:1595-1600.
  27. Kauppinen RA, Williams SR. Nuclear magnetic resonance spectroscopy studies of the brain. *Prog Neurobiol*. 1994;44:87-118.
  28. Miller BL. A review in chemical issues in 1H NMR spectroscopy: N-acetyl-L-aspartate, creatine and choline. *NMR Biomed*. 1991;4:47-52.
  29. Van der Grond J, Balm R, Kappelle LJ, Eikelboom BC, Mali WPTM. Cerebral metabolism of patients with stenosis or occlusion of the internal carotid artery: a <sup>1</sup>H-MR spectroscopic imaging study. *Stroke*. 1995;25:822-828.
  30. Graham SH, Blamire AM, Howseman AM, Rothman DL, Fayad PB, Brass LM, Petroff OA, Shulman RG, Prichard JW. Proton magnetic resonance spectroscopy of cerebral lactate and other metabolites in stroke patients. *Stroke*. 1992;23:333-340.
  31. Barker PB, Gillard JH, van Zijl PC, Soher BJ, Hanley DF, Agildere AM, Oppenheimer SM, Bryan RN. Acute stroke: evaluation with serial proton MR spectroscopic imaging. *Radiology*. 1994;192:723-732.
  32. Petroff OA, Graham GD, Blamire AM, Al-Rayess M, Rothman DL, Fayad PB, Brass LM, Shulman RG, Prichard JW. Spectroscopic imaging of stroke in humans: histopathology correlates of spectral changes. *Neurology*. 1992;42:1349-1354.
  33. Lopez Villegas D, Lenkinski RE, Wehrli SL, Ho WZ, Douglas SD. Lactate production by human monocytes/macrophages determined by proton MR spectroscopy. *Magn Reson Med*. 1995;34:32-38.
  34. Derdeyn CP, Grubb RL Jr, Powers WJ. Cerebral hemodynamic impairment: methods of measurement and association with stroke risk. *Neurology*. 1999;53:251-259.
  35. Silvestrini M, Troisi E, Matteis M, Cupini LM, Caltagirone C. Transcranial Doppler assessment of cerebrovascular reactivity in symptomatic and asymptomatic severe carotid stenosis. *Stroke*. 1996;27:1970-1973.
  36. Derdeyn CP, Yundt KD, Videen TO, Carpenter DA, Grubb RL, Powers WJ. Increased oxygen extraction fraction is associated with prior ischemic events in patients with carotid occlusion. *Stroke*. 1998;29:754-758.
  37. Hartl WH, Janssen I, Fürst H. Effect of carotid endarterectomy on patterns of cerebrovascular reactivity in patients with unilateral carotid artery stenosis. *Stroke*. 1994;25:1952-1957.
  38. Cikrit DF, Dalsing MC, Harting PS, Burt RW, Lalka SG, Sawchuk AP, Solooki B. Cerebral vascular reactivity assessed with acetazolamide single photon emission computer tomography scans before and after carotid endarterectomy. *Am J Surg*. 1997;174:193-197.
  39. D'Angelo V, Catapano G, Bozzini V, Catapano D, De Vivo P, Ciritella P, Parlato L. Cerebrovascular reactivity before and after carotid endarterectomy. *Surg Neurol*. 1999;51:321-326.
  40. Kleiser B, Widder B. Course of carotid artery occlusions with impaired cerebrovascular reactivity. *Stroke*. 1992;23:171-174.
  41. Vernieri F, Pasqualetti P, Passarelli F, Rossini PM, Silvestrini M. Outcome of carotid artery occlusion is predicted by cerebrovascular reactivity. *Stroke*. 1999;30:593-598.
  42. Yamauchi H, Fukuyama H, Nagahama Y, Oyanagi C, Okazawa H, Ueno M, Konishi J, Shio H. Long-term changes of hemodynamics and metabolism after carotid artery occlusion. *Neurology*. 2000;54:2095-2102.